

HYBRID PANCREATICODUODENECTOMY AS A TRANSITIONAL STRATEGY: OUTCOMES FROM A HIGH-VOLUME CENTER

Nguyen Quoc Thanh¹, Le Tien Dat^{1,2}, Tran Cong Duy Long^{1,2}

¹Hepatobiliary and Pancreatic Surgery Department, University Medical Center at Ho Chi Minh City, Ho Chi Minh City, Vietnam

²General Surgery Department, University of Medicine and Pharmacy at Ho Chi Minh City, Vietnam

ABSTRACT

Background: Minimally invasive pancreaticoduodenectomy (MIPD) has been increasingly adopted; however, its implementation remains challenging, particularly during the early phase of program development. Hybrid pancreaticoduodenectomy, combining laparoscopic resection with extracorporeal reconstruction, has been proposed as a transitional approach. This study aimed to evaluate the perioperative outcomes of hybrid pancreaticoduodenectomy in a real-world setting.

Methods: This retrospective study included consecutive patients undergoing hybrid pancreaticoduodenectomy at a high-volume tertiary referral center. To minimize selection bias, all patients who met predefined inclusion criteria during the study period were analyzed. Perioperative outcomes were assessed using standardized definitions, including postoperative pancreatic fistula (ISGPS 2016) and complications graded by the Clavien–Dindo classification.

Results: A total of 138 patients were included, representing a consecutive and unselected cohort. Preoperative conditions were generally within acceptable ranges, although a subset of patients presented with obstructive jaundice and acute cholangitis, with selected cases undergoing preoperative biliary drainage. Most patients had a low postoperative pancreatic fistula risk profile.

Perioperative outcomes were favorable. The median operative time was 277 minutes, and median blood loss was 200 mL. Major complications occurred in 6.5% of patients. Clinically relevant postoperative pancreatic fistula was observed in 8.7%, while most cases were biochemical leaks. The 90-day mortality rate was 1.4%.

Conclusions: Hybrid pancreaticoduodenectomy appears to be a safe and feasible approach with acceptable perioperative outcomes in a consecutive patient cohort. These findings support its role as a transitional strategy for the implementation of minimally invasive pancreatic surgery in routine clinical practice, while warranting cautious interpretation in the context of patient selection and study design.

Keywords: Hybrid pancreaticoduodenectomy, Pancreatic head lesions, Learning curve.

I. INTRODUCTION

Pancreaticoduodenectomy (PD) remains the standard surgical treatment for periampullary malignancies and a wide spectrum of lesions involving the pancreatic head. Despite improvements in perioperative management, PD continues to be associated with considerable morbidity, and optimizing surgical outcomes remains a major challenge [1, 2].

Minimally invasive pancreaticoduodenectomy (MIPD), encompassing robotic, laparoscopic and hybrid approaches, has been increasingly adopted over the past two decades. Accumulating evidence suggests that MIPD may offer advantages such as reduced intraoperative blood loss and enhanced postoperative recovery [3-5]. However, its broader implementation remains limited by technical complexity, a steep

Received: 10/02/2025. Revised: 26/3/2026. Accepted: 08/5/2026.

Corresponding author: Tran Cong Duy Long. Email: long.tcd@umc.edu.vn. Phone: (+84) 908237567

Hybrid pancreaticoduodenectomy as a transitional strategy...

learning curve, and persistent concerns regarding oncologic adequacy [6, 7].

Notably, high-quality evidence has not consistently demonstrated the superiority of MIPD over the conventional open approach. Randomized and observational studies have shown comparable perioperative and oncologic outcomes, indicating that MIPD is, at best, non-inferior when performed in appropriately selected patients and high-volume centers [8, 9]. Consequently, the role of MIPD should be interpreted within the context of surgeon experience and institutional expertise, rather than as a universally superior alternative.

In this setting, hybrid pancreaticoduodenectomy-combining laparoscopic resection with extracorporeal reconstruction-has emerged as a pragmatic transitional strategy to facilitate the safe adoption of minimally invasive techniques during the early learning phase. The Miami International Evidence-Based Guidelines further emphasize that MIPD should be implemented in a structured, stepwise manner and restricted to specialized centers with adequate training and case volume [10].

In Vietnam, minimally invasive pancreaticoduodenectomy (MIPD) has only recently been introduced, and evidence regarding its safety and feasibility remains limited, particularly during the early phase of adoption. Most available studies focus on highly selected patients, and real-world data from consecutive, unselected cohorts remain scarce. Therefore, this study aimed to evaluate the perioperative outcomes of hybrid pancreaticoduodenectomy in a consecutive series of patients at a high-volume tertiary referral center.

II. METHODS AND MATERIALS

2.1 Subjects

Inclusion criteria: Patients who underwent hybrid pancreaticoduodenectomy for lesions involving the pancreatic head or perampullary region, regardless of underlying pathology.

Exclusion criteria: Patients with incomplete clinical or pathological data.

2.2 Study methods

Study design: retrospective cohort study

Sample size and sampling method: All consecutive patients who met the inclusion and exclusion criteria and underwent MIPD at the University Medical Center in Ho Chi Minh City (UMC) between January 2019 and March 2026 were included in the study.

Surgical techniques:

Laparoscopic resection phase

Patients were placed in the supine position with slight reverse Trendelenburg. Pneumoperitoneum was established, and a standard multi-port laparoscopic approach was used.

Exploration of the abdominal cavity was performed to exclude metastatic disease. A conventional surgical approach was applied in all cases, without routine use of artery-first techniques. After opening the gastrocolic ligament, the lesser sac was entered to expose the pancreas. The right colon was mobilized, and a Kocher maneuver was performed to fully mobilize the duodenum and pancreatic head.

Dissection of the hepatoduodenal ligament was carried out, with identification and control of the common hepatic artery, gastroduodenal artery, and portal vein. The gastroduodenal artery was ligated and divided after confirming adequate hepatic arterial flow. The extent of lymphadenectomy and resection followed standard oncologic principles for perampullary malignancies.

The stomach or duodenum was transected depending on the type of resection (classic Whipple or pylorus-preserving). The proximal jejunum was divided and brought to the right side through a retromesenteric route. The pancreas was transected at the neck over the portal vein, followed by dissection of the uncinate process from the superior mesenteric vessels.

The specimen was completely mobilized laparoscopically and prepared for extraction.

Hybrid pancreaticoduodenectomy as a transitional strategy...

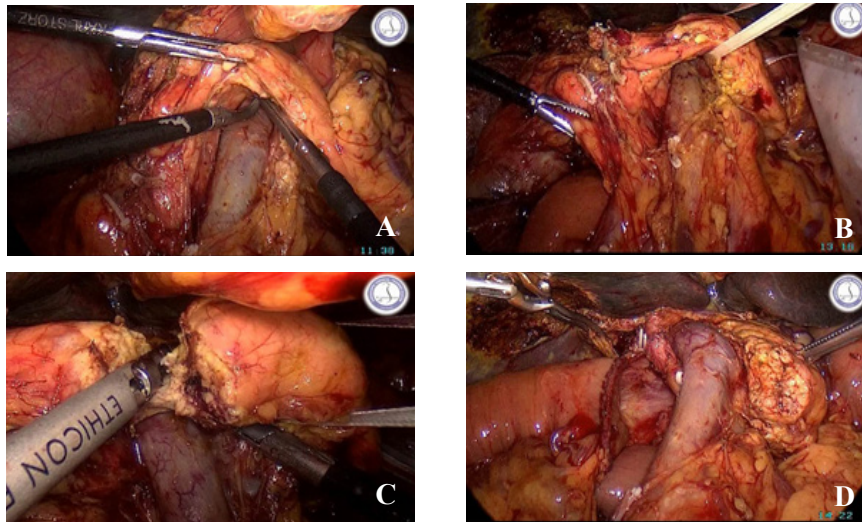


Figure 1: Laparoscopic resection phase of hybrid pancreaticoduodenectomy: pancreatic neck transection and uncinete dissection. (A) Exposure of the pancreatic neck over the portal vein. (B) Passage of a vessel loop (lacet) around the pancreatic neck for traction and control. (C) Transection of the pancreatic neck. (D) Completion of uncinete process dissection from the superior mesenteric vessels.

Extracorporeal reconstruction phase

A small upper midline laparotomy was performed for specimen extraction and reconstruction. Reconstruction was carried out in a standard fashion.

Pancreaticojejunostomy was performed using a modified Blumgart technique, with transpancreatic U-sutures placed between the pancreatic remnant and the jejunal seromuscular layer, combined with duct-to-mucosa anastomosis over an internal stent when appropriate.

Hepaticojejunostomy was constructed in an end-to-side fashion using continuous absorbable sutures. Gastrojejunostomy was subsequently performed.

Drains were routinely placed near the pancreaticojejunostomy and the hepaticojejunostomy. The abdominal incision was closed in layers after hemostasis was secured.

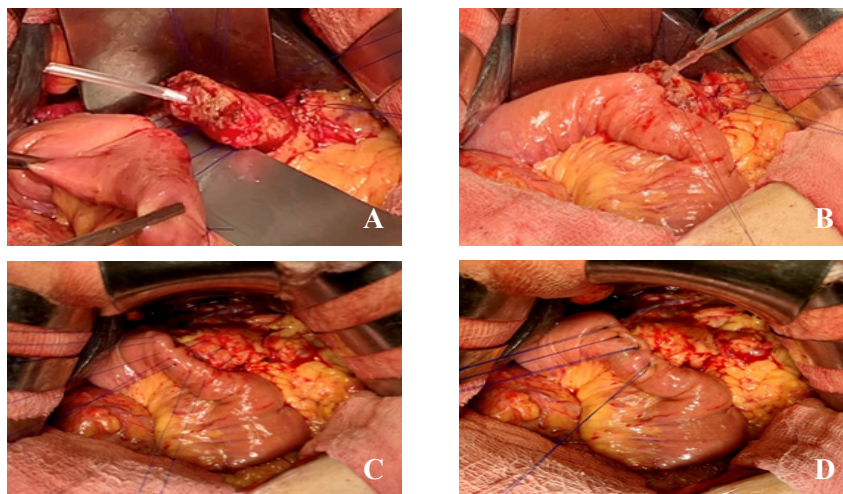


Figure 2: Extracorporeal reconstruction phase: pancreaticojejunostomy using the modified Blumgart technique. (A) Preparation of the pancreatic stump with placement of an internal pancreatic duct stent. (B) Duct-to-mucosa pancreaticojejunostomy using interrupted sutures. (C) Placement of transpancreatic U-sutures between the pancreatic remnant and the jejunal seromuscular layer. (D) Final configuration after completion of the modified Blumgart pancreaticojejunostomy.

Hybrid pancreaticoduodenectomy as a transitional strategy...

Study procedures:

Clinical data were collected from a prospectively maintained institutional database and electronic medical records.

Baseline characteristics included age, sex, body mass index (BMI), comorbidities, and preoperative laboratory parameters (hemoglobin, albumin, total bilirubin, and liver enzymes). Preoperative biliary drainage were also recorded.

Tumor characteristics included tumor location and pathological diagnosis.

Perioperative outcomes included operative time, estimated blood loss, and intraoperative transfusion. Technical success was defined as completion of the resection phase laparoscopically without conversion to open surgery, followed by planned extracorporeal reconstruction through a mini-laparotomy.

Postoperative complications were graded according to the Clavien–Dindo classification, with major complications defined as grade IIIA or higher. Procedure-specific complications, including postoperative pancreatic fistula (POPF), delayed gastric emptying (DGE), and post-pancreatectomy hemorrhage (PPH), were defined according to the International Study Group of Pancreatic Surgery (ISGPS).

2.3 Statistical analysis

Continuous variables were expressed as median (interquartile range), while categorical variables were presented as frequencies and percentages. Statistical analyses were performed using SPSS software (version 26.0, IBM Corp., Armonk, NY, USA).

III. RESULTS

3.1 Patient characteristics

To minimize selection bias, all consecutive patients undergoing hybrid pancreaticoduodenectomy during the study period were included in the analysis (n = 138).

Preoperative conditions were generally acceptable for major pancreatic surgery. Most patients had preserved nutritional and hematologic status, with laboratory parameters within clinically acceptable ranges (table 1). Approximately half of the patients required preoperative biliary drainage due to severe cholestasis and/or cholangitis using various approaches, including endoscopic and percutaneous techniques.

Regarding pancreatic risk profile, most patients had a low-risk fistula profile, with the majority

classified as negligible or low risk according to the Fistula Risk Score. Pancreatic duct size was also generally favorable.

Table 1: Baseline characteristics of patients undergoing hybrid PD

	Results (n = 138)
Age	64 (47 - 73)
Female, % (n)	47.9 (66)
BMI (kg/m ²)	22.2 (19.1 - 25.0)
ASA, % (n)	
- II	21.7 (30)
- III	78.3 (108)
Hb (g/dL)	11.0 (9.7 - 13.9)
Albumin (g/dL)	37.6 (29.7 - 42.9)
AST (U/L)	45.5 (20.0 - 82.0)
ALT (U/L)	78.5 (12.0 - 123.0)
Bilirubin (mg/dL)	2.8 (0.4 - 4.5)
Acute cholangitis, % (n)	25.4 (35)
Pre-operative biliary drainage, % (n)	
- No	54.3 (75)
- ERCP	17.4 (24)
- PTBD	23.9 (33)
- PTGBD	2.2 (3)
- Others	2.2 (3)
Amylase (U/L)	78.2 (17.0 - 915.0)
Lipase (U/L)	249.0 (0.4 - 920.0)
Pre-op CA 19-9 (U/L)	700.0 (11.0 - 765.7)
Pancreatic duct (mm)	3.0 (1.0 - 12.0)
Pancreatic texture, % (n)	
- Firm	44.9 (62)
- Soft	55.1 (76)
Fistula Risk Score, % (n)	
- Negligible	34.1 (47)
- Low	61.6 (85)
- Intermediate	4.3 (6)
- High	0.0 (0)
*Abbreviations: ERCP, endoscopic retrograde cholangiopancreatography; PTBD, percutaneous transhepatic biliary drainage; PTGBD, percutaneous transhepatic gallbladder drainage.	

Hybrid pancreaticoduodenectomy as a transitional strategy...

The indications for surgery reflected a typical spectrum of pancreatic head and periampullary diseases, predominantly malignant tumors, with pancreatic and ampullary cancers accounting for the majority, alongside less frequent benign or borderline lesions (Table 2). Based on preoperative imaging assessment, no patients in this cohort demonstrated major vascular involvement or invasion of adjacent organs (such as colonic involvement).

Table 2: Indications of hybrid PD

	Results (n = 138)
Pancreatic ductal adenocarcinoma (PDAC)	44.2% (61)
Ampullary adenocarcinoma (AAC)	29.0% (40)
Distal cholangiocarcinoma (dCCA)	13.0% (18)
Duodenal adenocarcinoma (DAC)	8.0% (11)
Intraductal papillary mucinous neoplasm (IPMN)	3.6% (5)
Neuroendocrine tumor (NET)	1.4% (2)
Solid pseudopapillary tumor (SPT)	0.7% (1)

3.2 Surgical outcomes

Perioperative outcomes demonstrated acceptable operative efficiency and safety (Table 3). The hybrid approach was successfully completed in most cases, with low intraoperative transfusion requirements. Conversion to open surgery occurred in 10 patients (7.2%). The main reasons included dense adhesions at the posterior pancreatic plane in five cases, intraoperative detection of colonic invasion in one case, and the need for portal vein resection due to tumor invasion in three cases. One conversion was due to uncontrolled intraoperative bleeding resulting from injury to a tributary of the Henle trunk draining into the portal vein.

Postoperative morbidity remained within acceptable limits, with a low rate of major complications. Major complications included

post-pancreatectomy hemorrhage (PPH) requiring reoperation in two cases (one due to bleeding from the stump of the gastroduodenal artery and one from the portal vein), as well as clinically relevant postoperative pancreatic fistula (POPF) requiring surgical revision of the pancreatic anastomosis in three patients. Delayed gastric emptying (DGE) was observed in four cases, including two managed endoscopically and two requiring surgical revision of the gastrojejunostomy.

Pancreatic fistula occurred predominantly as biochemical leak, while clinically relevant POPF was observed in a minority of patients. The overall postoperative course was favorable, with a reasonable length of hospital stay and low postoperative mortality.

Table 3: Perioperative and postoperative outcomes

	Results (n = 138)
Operative time (min)	277 (240 - 475)
Blood loss (mL)	200 (30 - 500)
Intraoperative transfusions, % (n)	7.2 (10)
Success-rate, % (n)	92.8 (128)
Hospital stays (days)	10 (7 - 30)
Major complications (Clavien \geq IIIA), % (n)	6.5 (9)
POPF:	
- No	69.5 (96)
- BL	21.7 (30)
- Grade B	6.5 (9)
- Grade C	2.2 (3)
90-day mortality, % (n)	1.4 (2)

IV. DISCUSSION

Pancreaticoduodenectomy remains one of the most complex abdominal procedures, with substantial morbidity even in high-volume centers. Large series and contemporary analyses have consistently reported non-negligible rates of postoperative complications, particularly pancreatic fistula and delayed recovery [1, 2]. In this context, minimally invasive approaches have been increasingly adopted with the aim of improving perioperative outcomes while maintaining surgical safety.

Hybrid pancreaticoduodenectomy as a transitional strategy...

In our cohort, perioperative outcomes were within acceptable ranges. The rates of major complications and clinically relevant postoperative pancreatic fistula were relatively low, and postoperative mortality remained minimal. These findings are notable given the inclusion of a consecutive, unselected patient population, reflecting routine clinical practice rather than highly selected cases. This suggests that hybrid pancreaticoduodenectomy can be safely implemented without compromising perioperative outcomes.

An important aspect of this study is the role of hybrid pancreaticoduodenectomy as a transitional strategy. During the early phase of adopting minimally invasive pancreatic surgery, hybrid techniques allow safe implementation by combining laparoscopic resection with extracorporeal reconstruction. This stepwise approach is consistent with the Miami International Evidence-Based Guidelines [10], which recommend structured implementation, appropriate patient selection, and performance in high-volume centers.

From a technical perspective, the favorable rate of pancreatic fistula may be partly explained by patient-related and procedural factors. Most patients in this cohort had a low fistula risk profile, with predominantly small pancreatic duct variability but overall favorable characteristics. The use of standardized reconstruction techniques, particularly the Blumgart pancreaticojejunostomy, may have contributed to improved anastomotic security and reduced pancreatic leak. These factors likely played a role in maintaining acceptable postoperative outcomes.

Another relevant observation is that the cohort included a spectrum of pathologies involving the pancreatic head and periampullary region, predominantly malignant diseases but also selected benign or borderline lesions. This heterogeneity further supports the generalizability of our findings and reflects real-world surgical indications rather than highly selected oncologic cohorts.

In addition, patients in this cohort generally did not exhibit major vascular involvement or adjacent organ invasion on preoperative assessment, reflecting a cautious selection strategy during the early phase of minimally invasive program

implementation. This should be considered when interpreting the generalizability of the findings. Notably, no vascular or adjacent organ involvement reported preoperatively may partly explain the need for conversion in a subset of patients.

The present study has several limitations. First, its retrospective design introduces inherent bias, although the inclusion of consecutive patients helps mitigate selection bias. Second, the lack of a control group precludes direct comparison with other surgical approaches. Third, long-term oncologic outcomes were not evaluated and require further investigation. Finally, this is a single-center experience, which may limit external generalizability.

Despite these limitations, this study provides valuable insight into the implementation of hybrid pancreaticoduodenectomy in a high-volume center. The use of a standardized surgical approach and consistent perioperative management likely contributed to the stability of outcomes observed. These findings suggest that hybrid pancreaticoduodenectomy represents a safe and practical strategy for the adoption of minimally invasive pancreatic surgery in routine clinical practice.

V. CONCLUSIONS

Hybrid pancreaticoduodenectomy is a safe and feasible approach with acceptable perioperative outcomes in a consecutive, unselected patient cohort. As a pragmatic transitional strategy, it facilitates the adoption of minimally invasive pancreatic surgery while maintaining procedural safety in routine clinical practice.

Disclosure

The authors declare that there is no conflict of interest regarding the publication of this article. All authors have read and approved the final version of the manuscript

REFERENCES

1. Cameron JL, He J. Two thousand consecutive pancreaticoduodenectomies. *J Am Coll Surg.* 2015; 220(4): 530-6.
2. Newhook TE, LaPar DJ, Lindberg JM, Bauer TW, Adams RB, Zaydfudim VM. Morbidity and mortality of

Hybrid pancreaticoduodenectomy as a transitional strategy...

- pancreaticoduodenectomy for benign and premalignant pancreatic neoplasms. *J Gastrointest Surg.* 2015; 19(6): 1072-7.
3. Joseph N, Varghese C, Lucocq J, McGuinness MJ, Tingle S, Marchegiani G, et al. Network Meta-Analysis and Trial Sequential Analysis of Randomised Controlled Trials Comparing Robotic, Laparoscopic, and Open Pancreatoduodenectomy. *Ann Surg Open.* 2024; 5(4): e507.
 4. Aiolfi A, Lombardo F, Bonitta G, Danelli P, Bona D. Systematic review and updated network meta-analysis comparing open, laparoscopic, and robotic pancreaticoduodenectomy. *Updates Surg.* 2021; 73(3): 909-922.
 5. Pfister M, Probst P, Muller PC, Antony P, Klotz R, Kalkum E, et al. Minimally invasive versus open pancreatic surgery: meta-analysis of randomized clinical trials. *BJS Open.* 2023; 7(2).
 6. Wang M, Li D, Chen R, Huang X, Li J, Liu Y, et al. Laparoscopic versus open pancreatoduodenectomy for pancreatic or periampullary tumours: a multicentre, open-label, randomised controlled trial. *Lancet Gastroenterol Hepatol.* 2021; 6(6): 438-447.
 7. Katsuki R, Jo T, Yasunaga H, Kumazawa R, Uda K. Outcomes of laparoscopic versus open pancreatoduodenectomy: A nationwide retrospective cohort study. *Surgery.* 2021; 169(6): 1427-1433.
 8. Wang M, Pan S, Qin T, Xu X, Huang X, Liu J, et al. Short-Term Outcomes Following Laparoscopic vs Open Pancreaticoduodenectomy in Patients With Pancreatic Ductal Adenocarcinoma: A Randomized Clinical Trial. *JAMA Surg.* 2023; 158(12): 1245-1253.
 9. Xu S, Deng X, Wang S, Yu G, Liu J, Gong W. Short- and long-term outcomes after laparoscopic and open pancreatoduodenectomy for elderly patients: a propensity score-matched study. *BMC Geriatr.* 2024; 24(1): 462.
 10. Asbun HJ, Moekotte AL, Vissers FL, Kunzler F, Cipriani F, Alseidi A, et al. The Miami International Evidence-based Guidelines on Minimally Invasive Pancreas Resection. *Ann Surg.* 2020; 271(1): 1-14.