

THE ROLE OF TRICHOSCOPE IN DIAGNOSING SCALP PSORIASIS AND SEBORRHEIC DERMATITIS

Pham Dao Tuong Van¹, Ly Thi My Nhung²

¹Department of Dermatology, Hue Central Hospital, Vietnam

²Department of Dermatology, University of Medicine and Pharmacy at Ho Chi Minh City, Vietnam

ABSTRACT

Objective: To characterize the trichoscopic features of scalp psoriasis and seborrheic dermatitis and to evaluate the diagnostic value of trichoscopy in differentiating these two conditions.

Methods: A descriptive case series was conducted at Ho Chi Minh City Hospital of Dermatology from March to August 2024. Eighty-seven adult patients clinically diagnosed with scalp psoriasis ($n = 50$) or seborrheic dermatitis ($n = 37$) were enrolled. Trichoscopic examination of representative lesions was performed using a Handyscope® device at $\times 10$ magnification. Vascular distribution, vessel morphology, erythema, and scale color were systematically recorded. The diagnostic performance of selected trichoscopic features was assessed using sensitivity, specificity, positive predictive value, and negative predictive value.

Results: Dotted vessels were observed in 84.0% of psoriasis cases and were absent in seborrheic dermatitis, showing 84.0% sensitivity and 100.0% specificity for psoriasis. Uniformly distributed vessels were also predominant in psoriasis (92.0% vs 18.9%). In contrast, arborizing vessels and non-uniform vascular distribution were more common in seborrheic dermatitis. White or silvery scales were more frequently observed in psoriasis, whereas yellow greasy scales appeared exclusively in seborrheic dermatitis, with 100.0% specificity for that diagnosis.

Conclusion: Trichoscopy is a useful non-invasive tool for differentiating scalp psoriasis from seborrheic dermatitis by identifying characteristic vascular and scaling patterns. Its routine use may improve diagnostic accuracy in clinical dermatology practice.

Keywords: Trichoscopy, scalp psoriasis, seborrheic dermatitis.

I. INTRODUCTION

Psoriasis and seborrheic dermatitis of the scalp are common chronic inflammatory dermatoses that often present with overlapping clinical features, making accurate diagnosis challenging. Trichoscopy is a non-invasive method for examining the scalp and hair follicles that has opened a new approach to identifying subtle microscopic features of the scalp [1-3]. Recent studies in Vietnam have begun to apply trichoscopy to scalp diseases, but data remain limited and inconsistent [4]. Therefore, we conducted this study to determine the prevalence of specific trichoscopic scalp features in psoriasis versus seborrheic

dermatitis and to assess the role of trichoscopy in distinguishing these two conditions. Our objectives were to quantify characteristic trichoscopic findings in scalp psoriasis and seborrheic dermatitis and to evaluate how trichoscopy may support clinical differentiation between these diagnoses.

II. SUBJECTS AND METHODS

2.1. Study design

This was a descriptive case series conducted from March to August 2024.

2.2. Participants

We enrolled adult patients (≥ 18 years) presenting to the outpatient clinic of Ho Chi Minh City Hospital

Received: 26/01/2025. Revised: 07/3/2026. Accepted: 08/5/2026.

Corresponding author: Ly Thi My Nhung. Email: nhungly@ump.edu.vn. Phone: (+84) 984 410 440

The role of trichoscope in diagnosing scalp psoriasis...

of Dermatology from March to August 2024 who were clinically diagnosed with scalp psoriasis or seborrheic dermatitis. Participants were recruited by convenience sampling. Patients with active scalp infections were excluded.

2.3. Clinical diagnostic criteria

All diagnoses were established clinically by board-certified dermatologists prior to trichoscopic examination. Scalp psoriasis was diagnosed based on the presence of well-demarcated erythematous plaques covered with thick, adherent silvery-white scales, often extending beyond the hairline, with or without involvement of typical extracutaneous psoriatic sites (elbows, knees, nails). Seborrheic dermatitis was diagnosed based on poorly demarcated erythematous patches with greasy yellowish scales distributed in seborrheic areas (scalp, nasolabial folds, eyebrows, retroauricular regions), accompanied by pruritus and a chronic relapsing course. In ambiguous cases with overlapping features, the consensus opinion of two senior dermatologists was used to confirm the clinical diagnosis. Patients with concomitant scalp dermatoses (e.g., tinea capitis, contact dermatitis), recent topical or systemic anti-inflammatory therapy within the preceding two weeks, or active scalp infection were excluded.

2.4. Data collection

Demographic data, clinical history, and the clinical diagnosis established as described above were recorded. Clinical examination was performed under natural light. Trichoscopic examination of two to three representative lesions per patient was then performed using a Handyscope® device (DermLite/FotoFinder, 3Gen, Inc., USA) at $\times 10$ magnification, in both polarized and non-polarized modes, with a glycol-based interface medium to ensure optimal vascular visualization. The trichoscopic images were systematically reviewed by investigators trained in trichoscopy for predefined vascular and scaling features, including vascular distribution (uniform or non-uniform), vessel morphology (dotted, comma-shaped, and arborizing vessels), erythematous background, and scale color (white, yellow, or white-yellow). To evaluate the diagnostic value of trichoscopy, the recorded features were compared with the prior clinical diagnosis, which

served as the reference standard for calculating sensitivity, specificity, positive predictive value, and negative predictive value.



Figure 1: Handyscope® FotoFinder dermatoscope (DermLite/FotoFinder, 3Gen, Inc., USA) used for the trichoscopic examinations.

2.5. Data collection procedure

All patients presenting with scalp disorders at the Outpatient Department who met the inclusion criteria were invited to participate in the study. After signing the informed consent form, the investigator explained the study objectives and procedures, collected demographic data and medical history, and performed a clinical examination. Lesion photographs were taken, data were recorded on the case report form, and trichoscopic examination was then performed using a trichoscope to capture magnified images.

2.6. Statistical Analysis

Data were entered in Excel and analyzed using Stata 16.0. Categorical variables are presented as frequencies and percentages, continuous variables as mean \pm SD. McNemar's test was used to compare paired categorical findings (naked eye vs. trichoscopy) within each disease group. Chi-square or Fisher's exact tests compared proportions between psoriasis and seborrheic dermatitis groups. Diagnostic performance of selected trichoscopic features was evaluated using sensitivity, specificity, positive predictive value (PPV), and negative predictive value (NPV), reported with 95% confidence intervals based on the Wilson score method. The clinical diagnosis served as the reference standard. A p-value < 0.05 was considered statistically significant.

2.7. Ethical consideration

All participants gave informed consent and the study was approved by the hospital’s ethics committee (Protocol 425/CN-BVDL, 29 Feb 2024).

III. RESULTS

During the study period, 87 patients were enrolled: 50 with scalp psoriasis (57.5%) and 37 with seborrheic dermatitis (42.5%).

The mean age was significantly higher in the psoriasis group than in the seborrheic group (48.9±15.4 vs. 34.9±15 years). In the psoriasis group, 29 patients (58.0%) were male and 21 (42.0%) female (M:F = 1.4:1). In the seborrheic dermatitis group, 16 patients (43.2%) were male and 21 (56.8%) female (M:F = 1:1.3) (Table 1).

Table 1: Patient Distribution by Age and Gender

Characteristic	Psoriasis (n = 50)	Seborrheic Dermatitis (n = 37)
Age (mean ± SD)	48.9 ± 15.4	34.9 ± 15
Age (range)	20 - 81	18 - 70
Male	29 (58.0)	16 (43.2)
Male : Female	1.4 : 1	1 : 1.3

Features such as uniformly distributed vessels, arborizing vessels, dotted vessels, and comma-shaped vessels showed statistically significant differences when observed by the naked eye versus trichoscopy (Table 2).

Table 2: Comparison of Lesions Observed by Naked Eye vs. Trichoscopy in Psoriasis

Characteristic	Psoriasis (n = 50)		p ^a
	Naked Eye	Trichoscope	
Vascular distribution			
Uniform	0 (0.0)	46 (92.0)	< 0.001
Non-uniform	0 (0.0)	4 (8.0)	0.1250
Vessel types			
Arborizing vessels	0 (0.0)	7 (14.0)	0.016
Dotted vessels	0 (0.0)	42 (84.0)	< 0.001
Comma-shaped vessels	0 (0.0)	26 (52.0)	< 0.001
Erythema	50 (100.0)	50 (100.0)	1.000
Scale color			
White	28 (56.0)	29 (58.0)	1.000
White-yellow	18 (36.0)	21 (42.0)	0.25
^a McNemar test			

The role of trichoscope in diagnosing scalp psoriasis...

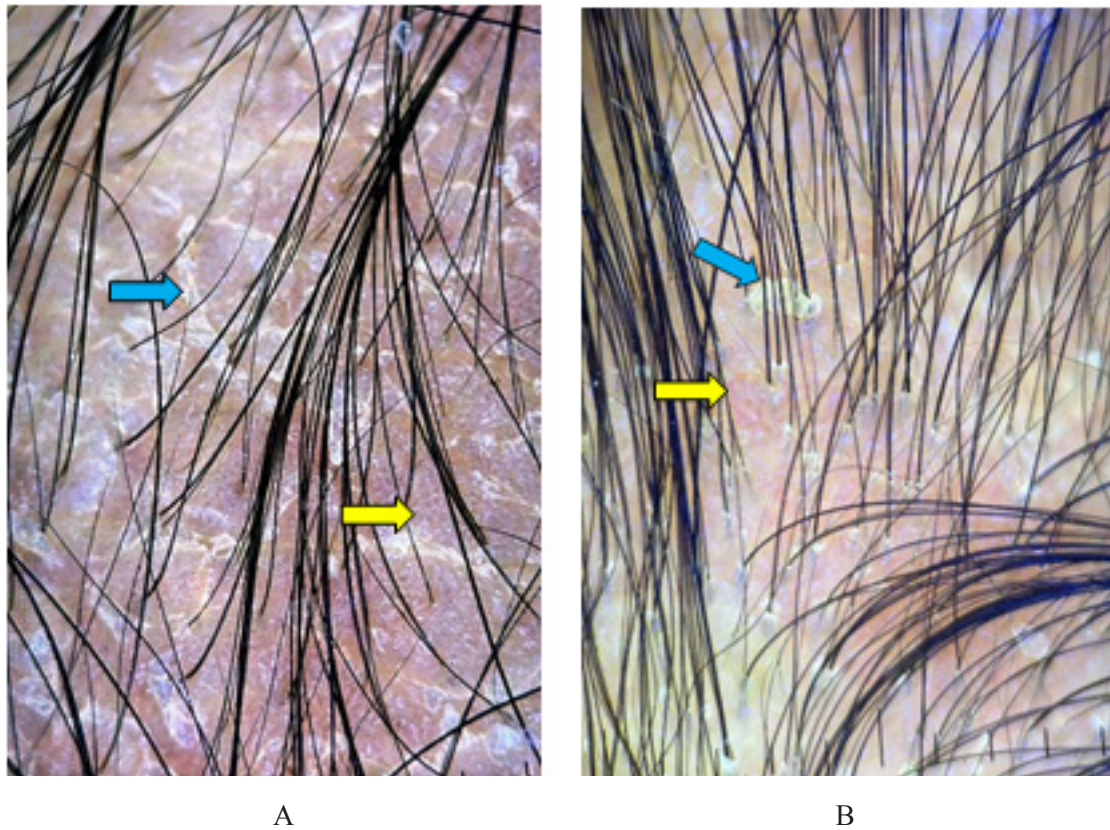


Figure 2: Trichoscopic features of scalp psoriasis (Handyscope®, ×10 magnification, polarized mode). (A) Uniformly distributed dotted vessels (yellow arrows) and silvery-white scales on an erythematous background (blue arrows). (B) Comma-shaped vessels with a non-uniform distribution (yellow arrows) and white-yellow scales on an erythematous background (blue arrows).

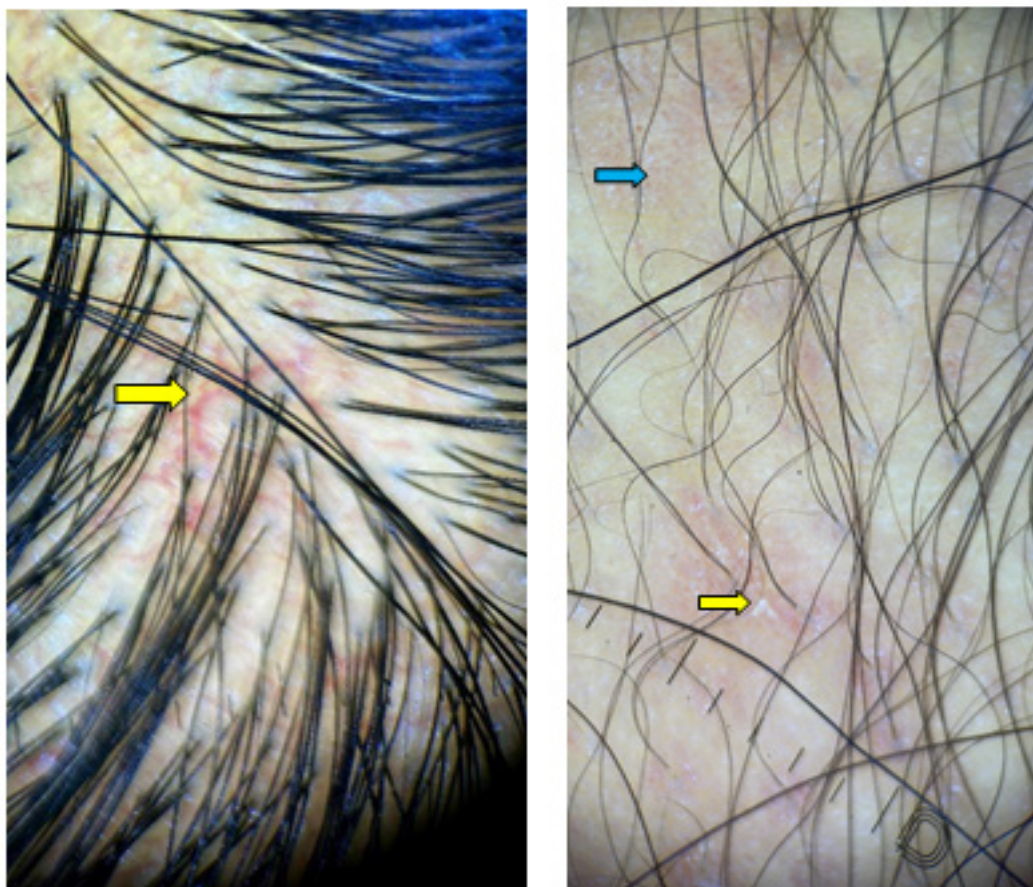
Vascular features including uniform and non-uniform distribution, arborizing vessels, and comma-shaped vessels demonstrated statistically significant differences between naked-eye observation and trichoscopic evaluation (Table 3).

Table 3: Comparison of Lesions Observed by Naked Eye vs. Trichoscopy in Seborrheic Dermatitis

Characteristic	Seborrheic Dermatitis (n = 37)		p ^a
	Naked Eye	Trichoscope	
Vascular distribution			
Uniform	0 (0.0)	7 (18.9)	0.016
Non-uniform	0 (0.0)	30 (81.1)	< 0.001
Vessel types			
Arborizing vessels	0 (0.0)	23 (62.2)	< 0.001
Comma-shaped vessels	0 (0.0)	25 (67.6)	< 0.001
Erythema	33 (89.2)	33 (89.2)	1.000

The role of trichoscope in diagnosing scalp psoriasis...

Characteristic	Seborrheic Dermatitis (n = 37)		p ^a
	Naked Eye	Trichoscope	
Scale color			
Yellow	10 (27.0)	12 (32.4)	0.5
White	3 (8.1)	5 (13.5)	0.5
White-yellow	15 (40.5)	18 (48.6)	0.25
^a McNemar test			



A

B

Figure 3: Trichoscopic features of scalp seborrheic dermatitis (Handyscope®, ×10 magnification, polarized mode). (A) Arborizing vessels with a non-uniform distribution (yellow arrows). (B) Comma-shaped vessels with a non-uniform distribution (blue arrows) and white scales on an erythematous background (yellow arrows).

In the psoriasis group, uniformly distributed vessels (92% vs. 19%, $p < 0.001$) and dotted vessels (84% vs. 0%, $p < 0.001$) were more frequently observed. In contrast, the seborrheic dermatitis group showed a higher prevalence of non-uniform vascular patterns (81% vs. 8%, $p < 0.001$) and arborizing vessels (62% vs. 14%, $p < 0.001$). White scales were more common in psoriasis (58% vs. 14%, $p = 0.002$), while yellow scales appeared exclusively in seborrheic dermatitis (32% vs. 0%, $p < 0.001$). Other features such as comma-shaped vessels, erythema, and white-yellow scales did not show statistically significant differences (Table 4).

The role of trichoscope in diagnosing scalp psoriasis...

Table 4: Comparison of Trichoscopic Findings Between Psoriasis and Seborrheic Dermatitis

Characteristic	Psoriasis (n = 50)	Seborrheic Dermatitis (n = 37)	p
Uniform vascular distribution	46 (92.0)	7 (18.9)	< 0.001 ^a
Non-uniform vascular	4 (8.0)	30 (81.1)	< 0.001 ^a
Arborizing vessels	7 (14.0)	23 (62.2)	< 0.001 ^b
Dotted vessels	42 (84.0)	0 (0.0)	< 0.001 ^a
Comma-shaped vessels	26 (52.0)	25 (67.6)	0.216 ^b
Erythema	50 (100.0)	33 (89.2)	0.074 ^a
Yellow scale	0 (0.0)	12 (32.4)	< 0.001 ^a
White scale	29 (58.0)	5 (13.5)	0.002 ^b
White-yellow scale	21 (42.0)	18 (48.6)	0.508 ^b

^aFisher's exact test; ^bChi-square test

For the diagnosis of scalp psoriasis, dotted vessels and yellow scales (the latter as a negative finding) showed perfect specificity (100%) and PPV (100%), supporting their value as “rule-in” signs. Sensitivity was highest for uniformly distributed vessels (92.0%) and dotted vessels (84.0%). For seborrheic dermatitis, yellow scales were highly specific (100%) but only moderately sensitive (32.4%), whereas non-uniform vascular distribution provided the best balance of sensitivity (81.1%) and specificity (92.0%) (Table 5).

Table 5: Diagnostic performance of selected trichoscopic features for differentiating scalp psoriasis from seborrheic dermatitis

Trichoscopic feature	Target diagnosis	Sensitivity (%)	Specificity (%)	PPV (%)	NPV (%)
Dotted vessels	Psoriasis	84.0 (71.5 - 91.7)	100.0 (90.6 - 100)	100.0 (91.6 - 100)	82.2 (68.7 - 90.7)
Uniform vascular distribution	Psoriasis	92.0 (81.2 - 96.8)	81.1 (65.8 - 90.5)	86.8 (75.2 - 93.5)	88.2 (73.4 - 95.3)
White (silvery) scales	Psoriasis	58.0 (44.2 - 70.6)	86.5 (72.0 - 94.1)	85.3 (69.9 - 93.6)	60.4 (46.9 - 72.4)
Yellow scales	Seborrheic dermatitis	32.4 (19.6 - 48.5)	100.0 (92.9 - 100)	100.0 (75.7 - 100)	66.7 (55.4 - 76.3)
Non-uniform vascular distribution	Seborrheic dermatitis	81.1 (65.8 - 90.5)	92.0 (81.2 - 96.8)	88.2 (73.4 - 95.3)	86.8 (75.2 - 93.5)
Arborizing vessels	Seborrheic dermatitis	62.2 (46.1 - 75.9)	86.0 (73.8 - 93.0)	76.7 (59.1 - 88.2)	75.4 (62.9 - 84.8)

Values are reported as percentage (95% confidence interval, Wilson score). The clinical diagnosis was used as the reference standard. PPV: positive predictive value; NPV: negative predictive value.

IV. DISCUSSION

Our study identified several clinical and trichoscopic features that help differentiate scalp psoriasis from seborrheic dermatitis. Regarding baseline characteristics, patients with psoriasis had a significantly higher mean age compared to those with seborrheic dermatitis (48.9 ± 15.4 vs. 34.9 ± 15 years), consistent with previous findings [4]. This difference aligns with the epidemiological and pathophysiological profile of seborrheic dermatitis, which tends to develop earlier in life and is closely linked to sebaceous gland activity, hormonal factors, and stress, especially among adolescents and middle-aged adults [5]. Concerning gender distribution, psoriasis cases showed a slight male predominance (male-to-female ratio 1.4:1), whereas seborrheic dermatitis was more frequent in females (ratio 1:1.3). Although some studies have reported higher incidence of seborrheic dermatitis in males due to the influence of androgens on sebaceous gland activity, our findings may reflect local demographic characteristics, healthcare-seeking behaviors, or sociocultural factors [5-7].

One of the most notable findings was the added value of trichoscopy in detecting microscopic vascular structures that are undetectable via naked-eye examination. While vascular features were rarely recorded clinically, trichoscopy significantly improved detection rates of distinct vessel morphologies ($p < 0.001$). This supports the role of trichoscopy as a valuable diagnostic tool, especially when clinical and histopathological presentations overlap [2, 4].

Vascular distribution emerged as a key diagnostic criterion. In our study, regularly distributed vessels were observed in 92% of psoriasis cases, whereas 81% of seborrheic dermatitis patients exhibited irregular vascular distribution ($p < 0.001$). This pattern has been described as a hallmark of scalp psoriasis by multiple authors, including [8], Halip (2025) [9] and Danh Bảo Khánh (2024) [4].

Morphologically, dotted vessels were the most characteristic finding of scalp psoriasis in our cohort (84%) and were absent in seborrheic dermatitis. This feature reflects the presence of dilated and tortuous capillary loops in elongated dermal papillae, an essential histopathologic hallmark of

psoriasis [9, 10]. Glomerular vessels and twisted loops are considered higher magnification variants of dotted vessels, and may reflect disease activity [8]. In contrast, arborizing vessels were dominant in seborrheic dermatitis (62%), much higher than in psoriasis (14%) ($p < 0.001$). Although Danh Bảo Khánh [4] noted that arborizing vessels are usually seen at $\times 20$ magnification or higher, we could detect them even with $\times 10$ magnification, suggesting their visibility at lower resolution. These thin, irregularly branched vessels correspond to superficial vascular dilatation in chronic inflammation associated with seborrhea, as previously described by Widaty (2019) [6] and Halip (2025) [9]. Comma vessels appeared in both conditions but were more prevalent in seborrheic dermatitis, indicating a possible diagnostic overlap. In practice, this feature should be interpreted with caution and in combination with the overall trichoscopic pattern [11].

In addition to vascular features, the characteristics of scale morphology provide further diagnostic value. White or silvery-white scales were predominantly observed in scalp psoriasis, whereas yellow, greasy scales were exclusive to seborrheic dermatitis ($p < 0.001$). This contrast reflects the underlying pathophysiology, parakeratosis with hyperproliferation in psoriasis versus desquamation mixed with sebum in seborrheic dermatitis [6, 8, 9]. The presence of yellow scales is considered a strong negative predictor of psoriasis, as highlighted in studies by Abdel-Azim (2017) and Halip (2025) [9, 12].

Recent studies integrating artificial intelligence in trichoscopic image analysis have achieved diagnostic accuracy and sensitivity exceeding 90%, supporting its use in primary care settings [13]. The combination of vascular and scaling features under trichoscopy enhances diagnostic precision and may reduce the need for invasive procedures such as scalp biopsies [4, 14]. However, trichoscopy should be interpreted within the broader clinical and patient history context to ensure appropriate use and prevent overreliance in daily practice.

Our findings are broadly concordant with those reported in other Asian populations, although several quantitative differences are worth noting. Kim et al. in Korea ($n = 96$) reported red dots/globules in 87% and glomerular vessels in 65% of

The role of trichoscope in diagnosing scalp psoriasis...

scalp psoriasis cases, while arborizing vessels were the dominant vascular pattern (49%) in seborrheic dermatitis [2]. Xavier et al. in India (n = 70) similarly identified red dots/globules in 93.3% of psoriasis cases and arborizing vessels in 82.5% of seborrheic dermatitis cases [14]. Widaty et al. in Indonesia (n = 96, seborrheic dermatitis only) found arborizing thin vessels in 38% and yellowish areas in 36% of patients [6]. The recent Vietnamese study by Danh Bảo Khánh and Văn Thế Trung (n = 174) reported uniformly distributed vessels in 91.75% of psoriasis cases and non-uniform distribution with comma-shaped vessels in seborrheic dermatitis (76.62%) [4], values closely mirroring our own (92.0% and 67.6%, respectively). The slightly higher prevalence of dotted vessels (84.0%) and lower prevalence of arborizing vessels in seborrheic dermatitis (62.2%) in our cohort, compared with the Korean and Indian series, may reflect differences in disease severity at presentation, lesion selection, magnification used (we restricted analysis to $\times 10$ magnification, whereas videodermatoscopy at $\times 20$ – $\times 70$ has been used elsewhere), and inter-observer variation in classifying overlapping vascular morphologies. Importantly, across all Asian series, including ours, dotted vessels emerge as the single most reproducible “rule-in” finding for scalp psoriasis, while yellow scales remain a highly specific marker of seborrheic dermatitis.

This study has several limitations. First, the sample size was relatively small and the two groups were imbalanced, which may have reduced statistical power and widened the confidence intervals of the diagnostic performance estimates. Second, this was a single-center study conducted at a tertiary dermatology hospital, potentially limiting generalizability to other settings and populations. Third, the clinical diagnosis served as the reference standard without histopathological confirmation, so overlap conditions such as seborrheic dermatitis could not be completely excluded. Fourth, all examinations were performed at $\times 10$ magnification, which may have limited the detection of additional vascular details visible at higher magnifications. Finally, trichoscopic interpretation was operator-dependent, and no inter-rater reliability or longitudinal follow-up analyses were performed. Larger multicenter

studies with histopathological correlation are needed to further validate these findings.

V. CONCLUSION

Trichoscopy proved to be a valuable tool for differentiating between scalp psoriasis and seborrheic dermatitis by identifying microscopic features invisible to the naked eye. Its clinical application can support diagnosis and guide therapeutic decisions, and should be integrated routinely into dermatological practice.

Conflict of interest

The authors declare that they have no conflict of interest.

REFERENCES

1. Rudnicka L, Rakowska A, Kerzeja M, Olszewska M. Hair shafts in trichoscopy: clues for diagnosis of hair and scalp diseases. *Dermatol Clin*. 2013; 31(4): 695-708, x.
2. Kim GW, Jung HJ, Ko HC, Kim MB, Lee WJ, Lee SJ, et al. Dermoscopy can be useful in differentiating scalp psoriasis from seborrheic dermatitis. *Br J Dermatol*. 2011; 164(3): 652-6.
3. Bruni F, Alessandrini A, Starace M, Orlando G, Piraccini BM. Clinical and trichoscopic features in various forms of scalp psoriasis. *J Eur Acad Dermatol Venereol*. 2021; 35(9): 1830-1837.
4. Danh Bảo Khánh, Văn Thế Trung. Đặc điểm tổn thương da đầu của vẩy nến và viêm da tiết bã qua phân tích bằng Dermoscopy. *Tạp chí Y học Việt Nam*. 2024; 542(2).
5. uzuncakmak tk. The differences of demographic features and seasonal variation in Seborrheic Dermatitis Between Adults And Children: A Cross-Sectional, Single-Center, Hospital-Based Study. *Southern Clinics of Istanbul Eurasia*. 2021.
6. Widaty S, Puspongoro EH, Rahmayunita G, Astriningrum R, Akhmad AM, Oktarina C, et al. Applicability of Trichoscopy in Scalp Seborrheic Dermatitis. *Int J Trichology*. 2019; 11(2): 43-48.
7. Lagace F, D’Aguanno K, Prosty C, Laverde-Saad A, Cattelan L, Ouchene L, et al. The Role of Sex and Gender in Dermatology - From Pathogenesis to Clinical Implications. *J Cutan Med Surg*. 2023; 27(4): NP1-NP36.
8. Waskiel-Burnat A, Czuwara J, Blicharz L, Olszewska M, Rudnicka L. Differential diagnosis of red scalp: the importance of trichoscopy. *Clin Exp Dermatol*. 2024; 49(9): 961-968.

The role of trichoscope in diagnosing scalp psoriasis...

9. Halip IA, Vata D, Patrascu AI, Temelie Olinici D, Popescu IA, Mocanu M, et al. The Role of Dermoscopy and High-Frequency Ultrasonography in the Diagnosis and Monitoring of Psoriasis Vulgaris. *Medicina (Kaunas)*. 2025; 61(11).
10. Ficicioglu S, Piskin S. Dermoscopic findings in psoriasis and seborrheic dermatitis on the scalp and correlation with disease severity. *Medicine Science | International Medical Journal*. 2018.
11. Kibar M, Aktan S, Bilgin M. Dermoscopic findings in scalp psoriasis and seborrheic dermatitis; two new signs; signet ring vessel and hidden hair. *Indian J Dermatol*. 2015; 60(1): 41-5.
12. Abdel-Azim NE, Ismail SA, Fathy E. Differentiation of pityriasis rubra pilaris from plaque psoriasis by dermoscopy. *Arch Dermatol Res*. 2017; 309(4): 311-314.
13. Yu Z, Kaizhi S, Jianwen H, Guanyu Y, Yonggang W. A deep learning-based approach toward differentiating scalp psoriasis and seborrheic dermatitis from dermoscopic images. *Front Med (Lausanne)*. 2022; 9: 965423.
14. Xavier GB. Dermoscopic features of scalp psoriasis and seborrheic dermatitis Among patients attending dermatology department of a tertiary care centre- a cross sectional study. *African Journal of Biomedical Research*. 2024: 2158-2169.